

ESC Working Group on Myocardial Function Position Paper: how to study the right ventricle in experimental models

Adelino F. Leite-Moreira^{1*†}, André P. Lourenço^{1†}, Jean-Luc Balligand²,
Johann Bauersachs³, Angela Clerk⁴, Leon J. De Windt⁵, Stephane Heymans⁶,
Denise Hilfiker-Kleiner⁷, Emilio Hirsch⁸, Guido Iaccarino⁹, Karol A. Kaminski¹⁰,
Ralph Knöll¹¹, Manuel Mayr¹², Guido Tarone⁸, Thomas Thum^{11,13}, and
Carlo G. Tocchetti¹⁴

¹Department of Physiology and Cardiothoracic Surgery, Faculty of Medicine, University of Porto, Al. Prof. Hernani Monteiro, 4200 319 Porto, Portugal; ²Institut de Recherche Expérimentale et Clinique (IREC), Pole de Pharmacologie et Thérapeutique (UCL-FATH), Université catholique de Louvain, Bruxelles, Belgium; ³Department of Cardiology and Angiology, Medizinische Hochschule—Hannover, Hannover, Germany; ⁴School of Biological Sciences, University of Reading, Reading, UK; ⁵Department of Cardiology, CARIM School for Cardiovascular Diseases, Maastricht University, Maastricht, The Netherlands; ⁶Center for Heart Failure Research, Cardiovascular Research Institute Maastricht (CARIM), Maastricht University, The Netherlands; ⁷Molecular Cardiology, Department of Cardiology and Angiology, Medizinische Hochschule—Hannover, Hannover, Germany; ⁸Dipartimento di Biotecnologie Molecolari e Scienze per la Salute, Università di Torino, Torino, Italy; ⁹Facoltà di Medicina, Università di Salerno, Baronissi, Salerno, Italy and IRCCS 'Multimedica', Milano, Italy; ¹⁰Department of Cardiology, Medical University of Białystok, Poland; ¹¹National Heart & Lung Institute, Imperial College London, UK; ¹²King's British Heart Foundation Centre, King's College London, London, UK; ¹³Institute of Molecular and Translational Therapeutic Strategies, Hannover Medical School, Hannover, Germany; and ¹⁴Clinica Montevegino, Mercogliano (AV), Italy

Received 2 September 2013; revised 25 November 2013; accepted 17 January 2014; online publish-ahead-of-print 23 February 2014

The right ventricle has become an increasing focus in cardiovascular research. In this position paper, we give a brief overview of the specific pathophysiological features of the right ventricle, with particular emphasis on functional and molecular modifications as well as therapeutic strategies in chronic overload, highlighting the differences from the left ventricle. Importantly, we put together recommendations on promising topics of research in the field, experimental study design, and functional evaluation of the right ventricle in experimental models, from non-invasive methodologies to haemodynamic evaluation and *ex vivo* set-ups.

Keywords Right ventricle function • Chronic overload • Functional evaluation • Cardiac imaging • Haemodynamics • Experimental myocardial preparations

Introduction

While for centuries the right ventricle (RV) was forgotten, in recent years it has become a priority in cardiovascular research. The RV has a fundamental prognostic relevance and plays a crucial role in pulmonary hypertension (PH). Additionally, a growing population with corrected congenital heart disease in whom the RV is the main concern now presents itself to the clinician. The development, anatomy, and function of the RV myocardium as well as its response to pathology and therapy are markedly different from those of the left ventricle (LV),¹ thus the RV cannot be comprehended

simply by extrapolating knowledge on LV physiology. An awareness statement of the National Heart, Lung, and Blood Institute with the focus on the RV was made in 2006;² after several years, in this position paper we discuss new topics in the growing field of RV research and we lay out recommendations for experimental functional evaluation.

Right ventricular physiology

RV development and anatomy are briefly reviewed in *Figure 1* and *Table 1*. The main role of the RV is to pump blood through the lungs

*Corresponding author. Tel: +351 22 5513644, Fax: +351 22 5513646, Email: amoreira@med.up.pt

†These two authors contributed equally to this work.

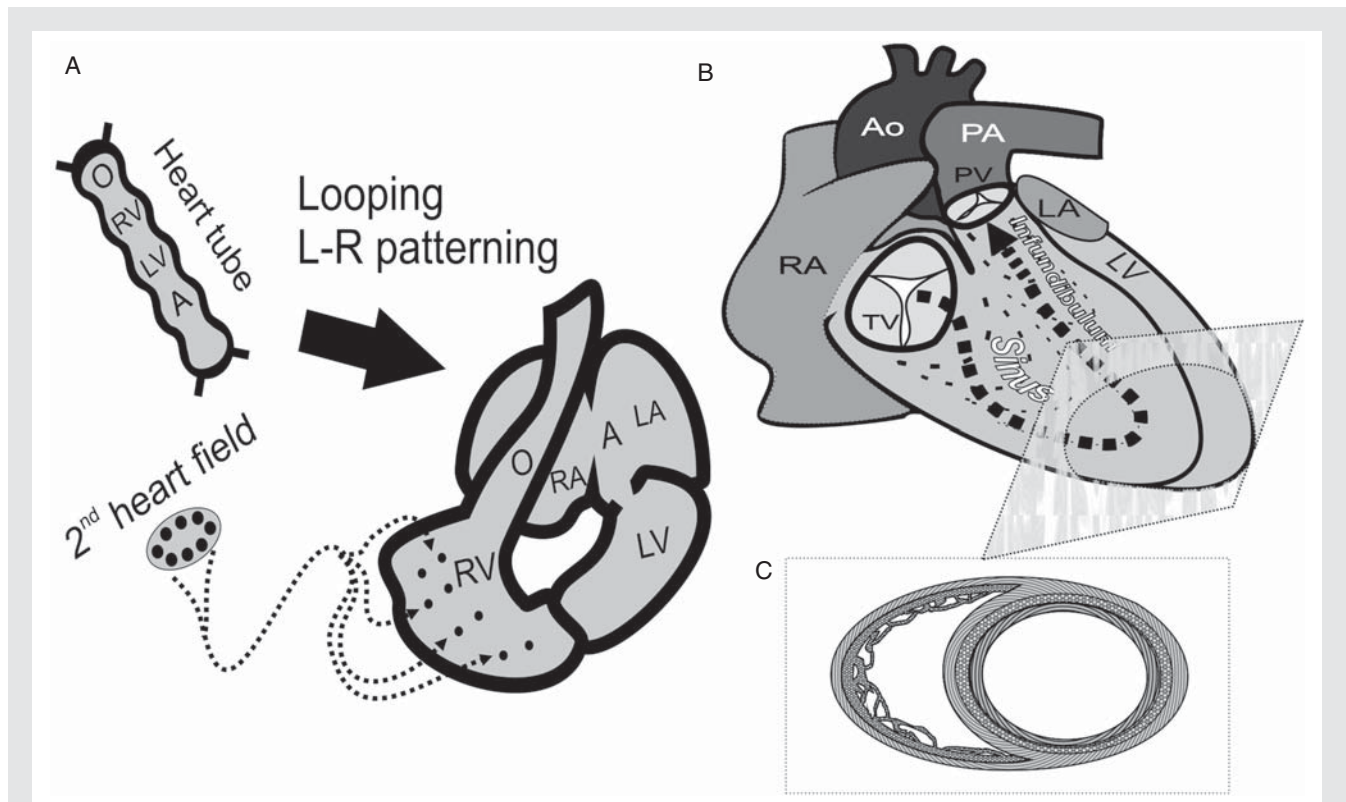


Figure 1 Right ventricular development and anatomy. The heart primordium is a tubular structure. A complex process of looping conducted by left–right (L–R) patterning transforms it into a highly asymmetric four-chamber completely septated mature organ. The right ventricle is the last component to develop, and may partly derive from a second heart field. Establishing two circulatory systems was essential to terrestrial life adaptation and homeothermy (A). The right ventricle is composed of a sinus and an infundibulum. The latter is recognizable at early stages of phylogenetic development, whereas the former can only be identified in vertebrates adapted to air breathing, constituting the main right ventricular pump element (B). In contrast to the left ventricle, the right ventricular sinus has only two layers of myocardium, an inner longitudinal and an outer circular layer (C). O, outflow tract; RV, right ventricle; LV, left ventricle; A, atrium; RA, right atrium; LA, left atrium; Ao, aorta; PA, pulmonary artery; PV, pulmonary valve; TV, tricuspid valve.

for gas transfer. The unique pulmonary vascular territory receives the whole cardiac output (CO) with a low resistance; therefore, RV developed pressure and energy cost of contraction are much lower than in the LV (Figure 2) which translates into thinner walls and lower mass.³ Lower pulmonary artery (PA) pressures (PAPs), however, also entail an increased pulsatile and wasted oscillatory power component (Figure 2).⁴ Moreover, low pressure and thoracic location make the RV remarkably sensitive to respiratory fluctuations. Inspiration conspicuously extends ejection, giving rise to physiological splitting of the second heart sound. The compliant RV adapts well to preload but is less responsive in terms of inotropy.¹ Several compensatory mechanisms boost RV performance. Higher volumes reduce excursion needed to achieve any stroke volume (SV).³ Low resistance of the pulmonary vascular bed eases ejection and hastens pressure fall. Indeed, PAP drop lags behind RV pressure fall, the momentum of RV SV maintains flow against the gradient during this 'hangout period', and the dicrotic notch [pulmonary valve (PV) closure] is delayed (Figure 2). Moreover, the LV substantially contributes to RV performance due to the presence

of shared fibre bundles, attachment to the interventricular septum (IVS), and pressure transmission through the IVS.

Influence of gender and hormones on right ventricular structure and function

Hormonal influences have been recently investigated in the large cardiovascular disease-free ethnically and racially diverse cohort of the Multi-Ethnic Study of Atherosclerosis (MESA-RV study). Women's RV ejection fraction (EF) is ~7% higher than that of men, whereas RV mass and volume are lower. Oestradiol levels correlate positively with RV systolic function in post-menopausal women under hormone replacement therapy, suggesting a clinically relevant improvement, while androgens are associated with increased mass in both men and post-menopausal women.⁵ Paradoxically, though female gender is the clearest risk factor for idiopathic pulmonary arterial hypertension (PAH), men have worse outcome.⁶

Table 1 Comparative features of right and left ventricular anatomy

	Right ventricle	Left ventricle
Shape	Complex: triangular (side view) and crescent (cross-section)	Simple: ellipsoid
Location	Anterior (substernal)	Posterior
Semilunar and AV valves	Separated by myocardium	Continuous
AV valve	More apical implantation, tricuspid	More basal implantation, bicuspid
Inflow and outflow tracts	Nearly at right angles	Almost at 180° to each other
Interventricular septum	Right convexity	
Mass	Lower (1/6)	Higher
Volume	Higher	Lower
Papillary muscles	>3	2
Trabeculations	Coarse	Fine
Muscle layers	2	3

Anatomic features of the right and left ventricles are compared. AV, atrioventricular.

Acute and chronic response to hypoxaemia

Severe hypoxia has a well-recognized myocardial depressing effect, and hypoxic pulmonary vasoconstriction would be presumed to induce major functional changes. Strangely, despite anecdotal reports of acute RV failure, healthy lowlanders show only mildly impaired diastolic function indexes after acute acclimatization⁷ and dogs respond to acute hypoxia with preserved RV function and ventriculo-vascular coupling (VVC).⁸ After acclimatization, tissue needs will ultimately be met by adaptations such as increased oxygen extraction and polycythaemia. RV function is reasonably preserved despite the high PAP, though maximum achievable CO during exercise may be jeopardized by low RV reserve.⁹

Response to exercise and influence of chronic physical activity on right ventricular structure and function

The RV and pulmonary circulation responses to exercise have been extensively reviewed elsewhere.¹⁰ With endurance training, the degree of LV and RV volume and mass increase is comparable and proportionate to maximum O₂ consumption. An independent correlation between physical exertion and RV volume and mass has been demonstrated in a large untrained population.¹¹ Dynamic exercise can markedly increase CO and PAP. Ultraendurance athletes may show acute myocardial injury and transient RV dysfunction,¹² but Olympic athletes have no long-term disturbances of RV function indexes,¹³ suggesting that any injury induced by excessive exercise is rapidly reversible.¹² Benefits from exercise training have been recognized in stable but not end-stage experimental and clinical PH.^{14,15}

Right ventricular hypertrophy and failure

Despite compensatory mechanisms, the RV is unable to cope with suddenly imposed afterload, and dilates.¹ Chronic volume overload is better tolerated than pressure overload. The latter usually advances swiftly towards failure unless it is imposed on a previously hypertrophied myocardium.¹⁶ The chronically overloaded RV adapts by way of hypertrophy, preload reserve recruitment, geometric adaptation,¹⁷ and change of activation sequence.¹⁸ The RV increases its developed pressure and wall stress (WS) in order to preserve CO against increased pulmonary vascular resistance (PVR).¹⁷ The fundamental determinants of survival are not PAP or PVR, but rather RV function and CO;^{19,20} symptoms may develop without correlation to PAP that may actually decrease as disease progresses (Figure 3). RV failure should be viewed as a state of mechanical uncoupling. The concept of VVC was first applied to the LV from pressure–volume (P–V) loop analysis. An index is obtained from the ratio between ventricular and arterial elastances: the end-systolic (ES) elastance (E_{es}) to effective arterial elastance (E_a) ratio. The RV normally operates at values that confer optimal efficiency. Lower values denote progressively less efficient work, but a clear mismatch which jeopardizes stroke work is only evident for values <1 (Figure 3).²¹ Disproportionate increases in the oscillatory power fraction that contribute to LV inefficiency in systemic arterial hypertension have been ruled out in PH.⁴ Nevertheless, the high ratio of pulsatile work accentuates the need for treatment strategies that improve arterial elasticity and disclose the incompleteness of PVR in RV afterload assessment. Flow is constrained by backward wave reflection from the whole pulmonary vascular bed. To describe all forces that dynamically oppose RV ejection, the full pulmonary vascular shifting pulsatile pressure and flow impedance spectrum must be analysed. Although elaborate, this analysis uncovers fundamental changes in proximal vessel stiffness that are associated with RV function independently of PVR.²²

Underlying molecular features

The RV myocardium undergoes complex molecular and cellular changes during adaptation to overload.^{2,17} Since development, anatomy, and physiology differ substantially from those of the LV it is likely that RV myocardial remodelling may assume particular features. Interestingly, based on microRNA (miR) sequencing, these novel and fundamental orchestrators of cardiac function seem to be unevenly distributed amongst cardiac structures,²³ clearly supporting that miR biology and therapeutic targetability will probably be distinctive in the RV. This field of knowledge merits intense future research. The progression towards dysfunction is heterogeneous amongst patients, possibly owing to genetic predisposition and the extent of neuroendocrine and inflammatory activation. A key concept is that mechanisms other than pressure overload must be involved, since PA banding (PAB) usually courses without RV failure. Ischaemia, energy depletion, and fibrosis have been proposed.¹⁷ Indeed, RV mechanical inefficiency was

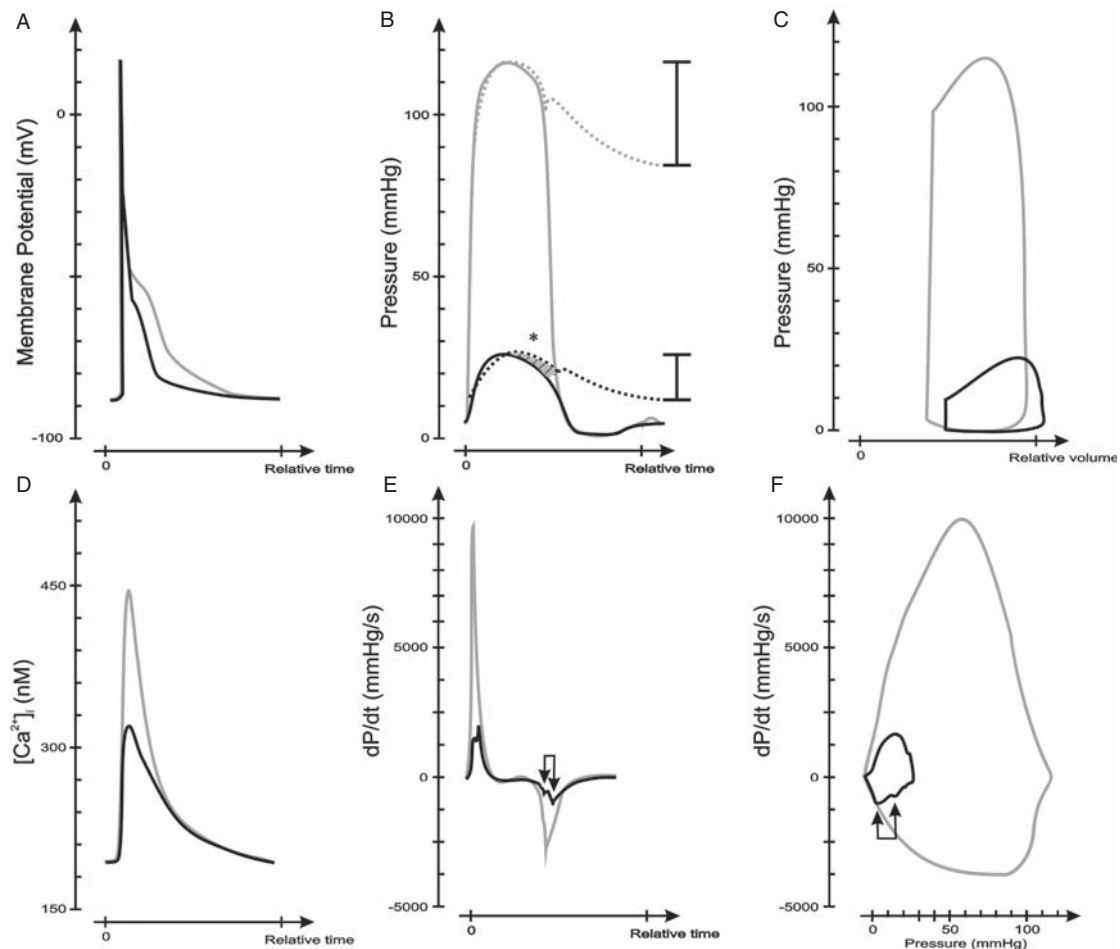


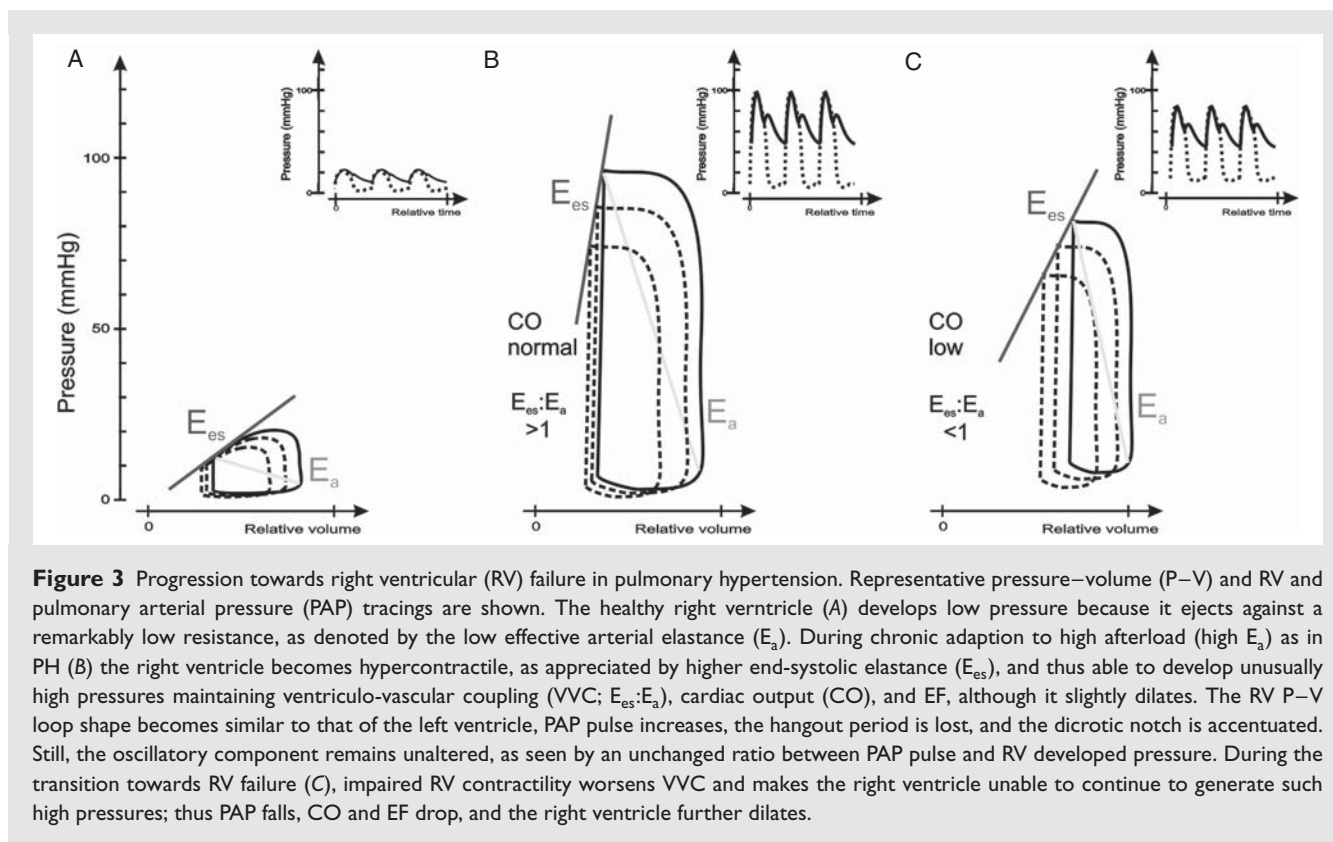
Figure 2 Comparative features of right and left ventricular cardiac physiology. Right ventricular (RV; black) and left ventricular (LV; grey) tracings are compared. RV action potential has a faster repolarization period (A), and elicits a smaller magnitude calcium transient compared with the left ventricle (D). RV developed pressure is minor; pressure drop initiates earlier in systole while pulmonary artery pressure is sustained during a 'hangout period' (*) compared with the left ventricle. Likewise, the fraction of oscillatory power is higher in the right ventricle as seen by the greater pulse pressure to developed pressure ratio (B). The pressure derivative (dP/dt) in the right ventricle conspicuously shows smaller peaks with a jagged contour (arrows) reflecting LV activity. Of note, dP/dt fall initiates earlier and most of the pressure fall takes place before the minimum dP/dt (E). A corresponding representation can be seen in a phase plane plot (F), whereas the pressure–volume loop evidences higher RV end-diastolic volumes, lower ejection fraction, and lower stroke work compared with the left ventricle (C).

recently found to be strongly related to worsening RVEF in idiopathic PAH. In contrast to the healthy high O₂ extraction reserve, RV O₂ extraction is excessive in PAH patients even at rest, whereas O₂ expenditure becomes ineffective. Altogether, these findings suggest that myocardial metabolism may be a potentially relevant target in RV failure.²⁴ Many molecular pathways pinpointed in RV hypertrophy converge on increased protein synthesis and apoptosis resistance by activation of mammalian target of rapamycin.²⁵ Prompt molecular responses to acute overload may explain why RV dysfunction persists despite pressure relief and raise the possibility for early therapeutic intervention.²⁶ Apoptosis and cell proliferation are both activated. Survival signals are initially favoured, but lost when dysfunction ensues. Other key turning points are uncontrolled oxidative stress, impaired mitochondrial function and

biogenesis, and disrupted redox regulation.²⁷ Finally, although beta-adrenergic signalling becomes impaired, the use of beta-blockers is not indicated and is poorly tolerated in RV dysfunction.²⁸ Recently a proof of concept research questioned this, deserving future exploration.²⁹

Right ventricular dysplasia or cardiomyopathy

A separate form of RV cardiomyopathy is RV dysplasia (RVD), an inherited rare cardiomyopathy characterized by its propensity towards arrhythmia. Though imaging modalities also detect LV changes, most cases particularly target the RV. The pathological hallmark is fibro-fatty replacement, wall thinning, and dilation.



Diagnostic criteria have been revised, reinforcing the role of magnetic resonance imaging (MRI) and mutation detection.³⁰ Mutations in desmosomal and non-desmosomal proteins might be responsible for the underlying disturbances in cell–cell contact which may be hastened by haemodynamic load and exercise training.³¹ Genetic and environmental influences may favour RV involvement. The pathophysiology has been increasingly investigated in animal models.³²

Ventricular interdependence and left ventricular function in right ventricular overload

RV dilation has dramatic consequences on WS and oxygen demand, and eventually leads to tricuspid regurgitation (TR), which further dilates the RV.² Patients with PH show prolonged RV contraction and dyssynchrony due mainly to electrophysiological remodelling rather than right bundle branch block.³³ Asynchronous contraction disturbs RV ejection.³³ RV pacing can re-synchronize the time of LV and RV peak pressures, improving RV function.^{34,35} Lingering diastolic RV pressures and dilation paradoxically leftward shift the IVS, delaying mitral valve opening and hindering early LV filling. LV underfilling may also be due to decreased RV output, and intrinsic LV mechanisms of dysfunction have been described.³⁶ A low CO will further compromise RV perfusion and may precipitate fatal events.¹

Systemic consequences of right ventricular failure

RV failure can be defined as a complex syndrome of inability to fill or eject, which manifests itself by fluid retention, low CO, and arrhythmia. These have important consequences, such as neuroendocrine and inflammatory activation and cardiac cachexia, which further contribute to deterioration.^{37,38} Furthermore, in PH and progressive RV dysfunction, baroreflex becomes impaired, contributing to further cardiac distension.³⁹

Therapeutic approaches to right ventricular failure

Preserving perfusion is crucial to uphold RV function. Preload and LV performance are other cornerstone determinants of RV function. While moderate volume loading improves performance, excessive load impairs CO through ventricular interdependence. General measures to reduce afterload, such as prevention of hypoxaemia and hypercapnia, to optimize tissue O_2 delivery, such as maintenance of haematocrit, as well as to uphold sinus rhythm are recommended.⁴⁰ These measures are insufficient in many circumstances, however, warranting pulmonary vasodilators. During the last decades, a substantial research effort to treat PAH yielded new effective PA vasodilators. Meanwhile, the research community became increasingly aware of the role of RV function and of the impact of PH of other aetiologies.¹⁹ Paradoxically, we know very

little about the impact of PA vasodilators in the myocardium.^{17,38,41} Bosentan improves CO and RV systolic function in PAH.⁴² Sildenafil increases CO and reduces RV mass and dilation, partly due to direct myocardial antihypertrophic effects.⁴³ The increased recognition of the pathophysiological and prognostic role of RV function advises new approaches targeting the myocardium. Growing research in experimental animal PH has focused on the RV as a therapeutic target, with promising results for beta-blockade²⁹ and metabolic modulation,⁴⁴ but there is still no translation to the clinics. Low dose dobutamine increases CO and decreases PVR without peripheral vasoconstriction, faring better than norepinephrine in RV failure. Inodilator drugs such as phosphodiesterase type 3 inhibitors and the calcium sensitizer levosimendan, and RV support devices may constitute other important approaches.⁴⁰

Functional evaluation of the right ventricle

Overview of imaging methods in right ventricular evaluation

The location, complex geometry, and morphology of the RV make it particularly difficult to assess by imaging modalities. Echocardiography is the most used and first-line modality. Guidelines have been recently endorsed by the European Association of Echocardiography.⁴⁵ The main concern with echocardiography is the inadequacy of geometric assumptions. Currently cardiac MRI is considered as a reference method for RV volume and function assessment with high reproducibility. MRI and contrasted chest computed tomography may constitute important complements in RV assessment although reference values have not been validated and their application is not widespread. Non-volumetric methods have expanded the possibilities of echocardiography. Tricuspid annular plane systolic excursion, which takes advantage of the predominant RV longitudinal shortening, correlates variably with RVEF and is highly load dependent, while myocardial acceleration during isovolumetric contraction assessed by tissue Doppler is a load-independent index of contractility which correlates well with E_{es} in the physiological range. Myocardial performance (or Tei) index evaluates overall performance. New imaging modalities and echocardiography indexes are increasingly used in animal research as steps towards non-invasive evaluation.⁴⁶ High-resolution cine-MRI and echocardiography using high-field strength technology and high-frequency probes, respectively, have allowed not only a better assessment of RV anatomy but also a non-invasive evaluation of function.^{46,47} Although still quite expensive and not widespread, they will hopefully allow serial monitoring of function devoid of deep anaesthetic and surgical interference. MRI has been increasingly used to evaluate the RV in mouse models.⁴⁸ PA compliance can be estimated by its flow contour. With PH, PA flow contour progressively loses its roundness and symmetry, becoming triangular, it shortens acceleration time (PAAT) and develops an early systolic notching due to wave reflection. CO measured by either echocardiography or MRI correlates well with thermodilution, whereas PAAT correlates inversely with mean PAP.⁴⁶ Estimation of systolic

PAP from the velocity of TR based on Bernoulli's equation that is customary in the clinic is rarely feasible in rodent models due to late appearance and technical limitations. Although it requires good time resolution, balanced gain-scale settings, and correction for cycle or ejection length, PAAT is a reliable alternative for PAP estimation in animal models.⁴⁷

Right ventricular biomarkers

Levels of NT-proBNP relate to the progression of RV dysfunction and identify subgroups with worse prognosis.⁴⁹ Matrix metallo-proteinase 9 levels are independently associated with lower mass and RV end-diastolic (ED) volume, whereas plasminogen activator inhibitor-1 levels are related to decreased EF, insinuating subclinical increases in PVR.⁵⁰ Novel miR-based biomarkers might soon be available, but those shown useful in LV failure may not behave as such in RV failure, as demonstrated for systemic ventricles after atrial repair for transposition of the great arteries.⁵¹

Exercise testing

Although exercise performance may be conditioned by respiratory effort, lung pathology, muscle mass wasting, and deterioration of whole body metabolism, it has understandably been used to assess functional status in RV disease models because it is analogous to the 6 min walk test or the cardiopulmonary exercise test. Both voluntary and mandatory endurance tests have been used.^{14,52,53} While in humans cardiopulmonary testing at maximal exertion provides valuable insights into RV and cardiac function,¹⁵ the equivalent testing has not been performed in animal models.

Haemodynamic evaluation

Most invasive evaluations are not compatible with serial follow-up. Even so, telemetry monitoring of PAP has been described after thoracotomy in rodents.⁵⁴ Less invasive methods of catheter placement in the PA and RV through trans-diaphragmatic and jugular vein approaches have also been reported.^{46,55} Though technically demanding and prone to several caveats, catheter-based methods are the gold standard in pressure measurement. PAP is frequently estimated from RV pressure, and PVR can be derived by further measuring CO and considering left atrial pressure negligible. Optimally, measurements should be made in closed-chest unanaesthetized animals because deep anaesthesia and open thorax without adequate fluid replacement can easily lead to underestimation of CO, but an open-thorax approach is preferable to assess RV function independently of ventricular interaction. RV pressure curve analysis can be particularly informative, but interpretation requires caution. No extrapolations should be made from LV experience. Pressure fall is remarkably different in the RV. Pressure derivative (dP/dt) becomes negative soon after maximal pressure, suggesting an early start of relaxation, whereas actual isovolumetric relaxation period starts later due to the hangout period. The time from onset to maximum rate of pressure fall (dP/dt_{min}) occupies nearly two-thirds of the duration of pressure fall and therefore most of relaxation takes place before dP/dt_{min} in the RV. Thus the

time constant of isovolumetric relaxation τ is not as representative of relaxation in the healthy RV.⁵⁶ The differences between ventricles may be due to distinct baseline loading conditions and differences in vascular impedance. Nevertheless, when RV afterload is raised, the pattern of RV pressure fall shows marked load dependency and becomes similar to LV pressure fall.⁵⁶ Also in systole, the positive phase of dP/dt shows a wide and commonly double-peaked contour in which the early component is ascribable to LV contraction. The RV shows a remarkable capacity to increase its contractility in response to afterload compared with the LV, as manifest by load dependency and marked increases in the relationship between dP/dt_{max} and ED dimensions.⁵⁶ This capacity, which is mainly due to homeometric autoregulation, helps preserve VVC in moderate chronic PH.²¹ Measures of volume or flow must be employed to estimate filling and performance. Echocardiography or imaging methods can be applied non-invasively but not in a real-time beat-to-beat basis. Thermodilution or flow measurement with transit time or electromagnetic probes are gold standard invasive methods that can be performed simultaneously with pressure recordings to quantify CO but are not informative on RV volume. Various methods have been employed to estimate RV volume jointly with pressure. Biplane cineventriculography with subsequent reconstruction of P–V loops, thermodilution PA catheters, real-time 3D echocardiography reconstruction, along with pressure recordings⁵⁷ and single beat estimation of isovolumetric RV pressures and MRI evaluation within 2 days⁵⁸ have been used in the clinical setting. Nevertheless, some assumptions underlying these methods may not be valid in PH. Undoubtedly the conductance methodology is the ideal approach to obtain the RV ES and ED P–V relationship-derived load-independent indexes, which convey fundamental information on myocardial function. To our knowledge, the conductance technique for continuous real-time RV volume measurement has only been employed anecdotally in the clinical setting.⁵⁹ Legitimate questions may be raised regarding the application of this methodology to the RV, because of its coarse trabeculations and complex geometry, and because ES determination is prone to error in triangular shaped loops.⁸ Briefly, complex geometry makes it almost impossible to scope RV volume fully by conductance; therefore, choice of catheter length, route of insertion, and positioning should be cautiously considered and CO should be determined by an independent method to calibrate for field inhomogeneity. Also, loss of electric current to neighbouring structures can be more pronounced, thus parallel conductance should be meticulously determined. Nevertheless, during the last decade, real-time measurement of RV volumes by conductance catheter has been widely validated in animals.⁶⁰ Load-independent ES and ED P–V relationship-derived indexes originally validated for the LV have been extensively validated for RV analysis as well, and are now widely used as an ideal mean to assess systolic and diastolic RV properties in experimental research.⁶¹ Moreover, *in vivo* haemodynamic assessment enables pharmacological stress testing with dobutamine.^{52,61}

Animal and experimental research

Although no model fully recapitulates human PH, they provide invaluable insight into its pathophysiology and therapeutics.⁶² Monocrotaline-induced PH is a simple, reproducible model of progressive pulmonary vasculopathy that reasonably mimics PAH and RV failure accompanied by extensive neuroendocrine and inflammatory activation and cardiac cachexia.³⁷ The main concerns regarding this model are a systemic toxic endothelial effect, which probably also induces myocarditis, a high mortality rate, and a limited reproducibility in mice.⁶³ PH in response to chronic hypoxia also involves a local inflammatory response but does not progress to severe PH and RV failure, with the exception of fawn-hooded rats. Slight model modifications have been implemented in order to better reproduce severe human PH, such as the administration of vascular endothelial growth factor receptor inhibitors and concomitant hypoxia, which is gaining increasing acceptance.⁶² A common denominator of most studies is the preferential focus on lung vascular remodelling over RV evaluation. Depending on the timing of intervention, degree of constriction, and animal species, the surgical model of RV pressure overload induced by PAB may either reveal a compensated hypertrophic phenotype with preserved CO, no dilation, and markedly increased systolic function indexes,⁶¹ consistent with the clinically compensated long-term evolution of patients with systemic RV⁶⁴ or dilation and low CO.⁵² Experimental models employed to mimic acute PH accompanying pulmonary thrombo-embolism are intravenous injection of clots or exogenous material such as microspheres. Vascular occlusion suddenly increases PAP, injuring the RV by stretch, ischaemia, and inflammatory response, particularly in the outflow tract.⁶⁵ Many other animal models have been used to assess RV dysfunction secondary to left heart, pulmonary, and congenital pathologies, as well as right-sided valve disease, but a detailed discussion is beyond the scope of this position paper.^{48,62}

Ex vivo evaluation

Although the original set-up was developed for LV evaluation, it is possible to insert a balloon in the RV along with a catheter tip manometer in a modified Langendorff preparation. This set-up enables evaluation of RV function without the influence of pericardium, systemic mediators, autonomic nervous system, and changing coronary perfusion. Simple analysis of pressure tracings allows the acquisition of relaxation and contractility indexes, but the capability to modify balloon volume or rate of electrical stimulation further permits the acquisition of P–V and pressure–frequency relationships. Additionally, if an LV balloon is coupled to the set-up, it will also enable the assessment of ventricular interaction.^{35,52} In a new development, Piao *et al.* have described a modified Langendorff preparation with working RV and simultaneous assessment of pressure, ejection, and RV work that allows acute pharmacological testing in the intact RV.⁴⁴ Many studies addressing modulation of myocardial function have been conducted in RV papillary or trabecular muscles due to their favourable morphology. These methods are used to evaluate function devoid of geometric or systemic confounders. When assessing the cardiomyocyte, the extracellular matrix component is also excluded.

Direct comparisons between RV and LV isolated myocytes reveal important differences.⁶⁶

Systems biology approach

Unbiased discovery approaches that are not limited to known molecules of presumed importance are pivotal to interrogate differences between the RV and LV at a molecular level. '-Omics' methods enable screening of thousands of molecules without *a priori* assumptions. Transcriptomics and next-generation sequencing—the analysis of mRNA and also non-coding RNAs—can provide information on cellular activity, but they only provide a snapshot of gene expression. In comparison, proteomics—the analysis of proteins—offers the distinct advantage that the actual protein content in the tissue represents the net effect of protein synthesis and degradation. Also, certain proteins, i.e. components of the extracellular matrix, accumulate over time. The Human Protein Atlas project (www.proteinatlas.org) aims to generate antibodies to all proteins encoded by the human genome and to probe *in vivo* protein location in different tissues.⁶⁷ Nonetheless, different areas, in particular the RV and LV, are not compared. Importantly, there are inherent limitations of antibody-based detection of proteins such as antibody specificity and epitope masking. Negative immunostaining does not necessarily indicate the absence of a protein. The epitope may simply be masked. Mass spectrometry-based proteomics can investigate protein changes without the constraints of antibody-based detection.⁶⁸

Conclusion

We believe that research on RV development, anatomy, physiology, and cell biology must continue to be fostered, keeping in mind that the RV is clearly distinct from the LV. Elucidating mechanisms of disease progression from compensated hypertrophy to failure is a major goal. Specific research on the effects that new PA vasodilator drugs have on RV function and remodelling is needed. New therapeutic approaches to treat PH should take into account RV function and remodelling; therefore, all studies should assess RV effects in detail. New drugs, devices, and gene or cell therapy that target the RV are awaited. When assessing RV function, an integrative approach from the *ex vivo* cardiomyocyte to the *in vivo* intact organism should be pursued, combining imaging methods with functional records and relevant post-mortem data such as liver weight and pleural effusion. To enable repeated acquisitions with minimum disturbances of physiology, lines of research that validate non-invasive RV function measurements or its surrogates should continue to be followed. Moreover, due to important interactions between ventricles, LV function or at least systemic pressures should be concomitantly evaluated. Gender differences in RV physiology and their contribution to the pathogenesis of disease have been poorly explored as has the impact of exercise training on the prognosis of patients with PH whatever the aetiology. These topics deserve further research.

Funding

This work was supported by grants from Portuguese Foundation for Science and Technology (project nos PEst-C/SAU/UI0051/2011 and EXCL/BIM-MEC/0055/2012; partially funded by FEDER through COM-PETE) through the Cardiovascular R&D Unit and by European Commission Grant FP7-Health-2010; MEDIA-261409 to AFL-M and APL, grants from the Italian Society of Hypertension, and Italian Ministry of University and Research to GI, a grant from Foundation for Polish Science to KAK, and by grants from the German Federal Ministry of Education and Research (01EO1302) and Excellence Cluster REBIRTH to TT. MM is a Senior Fellow of the British Heart Foundation.

Conflict of interest: none declared.

References

- Haddad F, Couture P, Tousignant C, Denault AY. The right ventricle in cardiac surgery, a perioperative perspective: I. Anatomy, physiology, and assessment. *Anesth Analg* 2009;**108**:407–421.
- Voelkel NF, Quaife RA, Leinwand LA, Barst RJ, McGoon MD, Meldrum DR, Dupuis J, Long CS, Rubin LJ, Smart FW, Suzuki YJ, Gladwin M, Denholm EM, Gail DB. Right ventricular function and failure: report of a National Heart, Lung, and Blood Institute working group on cellular and molecular mechanisms of right heart failure. *Circulation* 2006;**114**:1883–1891.
- Lorenz CH, Walker ES, Morgan VL, Klein SS, Graham TP Jr. Normal human right and left ventricular mass, systolic function, and gender differences by cine magnetic resonance imaging. *J Cardiovasc Magn Reson* 1999;**1**:7–21.
- Saouti N, Westerhof N, Helderma F, Marcus JT, Boonstra A, Postmus PE, Vonk-Noordegraaf A. Right ventricular oscillatory power is a constant fraction of total power irrespective of pulmonary artery pressure. *Am J Respir Crit Care Med* 2010;**182**:1315–1320.
- Ventetuolo CE, Ouyang P, Bluemke DA, Tandri H, Barr RG, Bagiella E, Cappola AR, Bristow MR, Johnson C, Kronmal RA, Kizer JR, Lima JA, Kawut SM. Sex hormones are associated with right ventricular structure and function: the MESA-right ventricle study. *Am J Respir Crit Care Med* 2011;**183**:659–667.
- Kawut SM, Al-Naamani N, Agerstrand C, Rosenzweig EB, Rowan C, Barst RJ, Bergmann S, Horn EM. Determinants of right ventricular ejection fraction in pulmonary arterial hypertension. *Chest* 2009;**135**:752–759.
- Huez S, Faoro V, Guenard H, Martinot JB, Naeije R. Echocardiographic and tissue Doppler imaging of cardiac adaptation to high altitude in native highlanders versus acclimatized lowlanders. *Am J Cardiol* 2009;**103**:1605–1609.
- Brimioule S, Wauthy P, Ewalenko P, Rondelet B, Vermeulen F, Kerbaul F, Naeije R. Single-beat estimation of right ventricular end-systolic pressure–volume relationship. *Am J Physiol Heart Circ Physiol* 2003;**284**:H1625–H1630.
- Faoro V, Bolding S, Moreels M, Martinez S, Lamotte M, Unger P, Brimioule S, Huez S, Naeije R. Bosentan decreases pulmonary vascular resistance and improves exercise capacity in acute hypoxia. *Chest* 2009;**135**:1215–1222.
- Naeije R, Chesler N. Pulmonary circulation at exercise. *Comp Physiol* 2012;**2**:711–741.
- Aaron CP, Tandri H, Barr RG, Johnson WC, Bagiella E, Chahal H, Jain A, Kizer JR, Bertoni AG, Lima JA, Bluemke DA, Kawut SM. Physical activity and right ventricular structure and function: the MESA-right ventricle study. *Am J Respir Crit Care Med* 2011;**183**:396–404.
- La Gerche A, Burns AT, Mooney DJ, Inder WJ, Taylor AJ, Bogaert J, Macisaac AI, Heidbuchel H, Prior DL. Exercise-induced right ventricular dysfunction and structural remodelling in endurance athletes. *Eur Heart J* 2012;**33**:998–1006.
- Krol W, Braksator W, Kasprzak JD, Kuch M, Mamcarz A, Chybowska B, Krzysztofak H, Dluzniewski M. The influence of extreme mixed exertion load on the right ventricular dimensions and function in elite athletes: a tissue Doppler study. *Echocardiography* 2011;**28**:753–760.
- Handoko ML, de Man FS, Happe CM, Schlij I, Musters RJ, Westerhof N, Postmus PE, Paulus WJ, van der Laarse WJ, Vonk-Noordegraaf A. Opposite effects of training in rats with stable and progressive pulmonary hypertension. *Circulation* 2009;**120**:42–49.
- Mereles D, Ehken N, Kreuzer S, Ghofrani S, Hoepfer MM, Halank M, Meyer FJ, Karger G, Buss J, Juenger J, Holzapfel N, Opitz C, Winkler J, Herth FF, Wilkens H, Katus HA, Olschewski H, Grunig E. Exercise and respiratory training improve exercise capacity and quality of life in patients with severe chronic pulmonary hypertension. *Circulation* 2006;**114**:1482–1489.
- Hopkins WE. The remarkable right ventricle of patients with Eisenmenger syndrome. *Coron Artery Dis* 2005;**16**:19–25.

17. Bogaard HJ, Abe K, Vonk Noordegraaf A, Voelkel NF. The right ventricle under pressure: cellular and molecular mechanisms of right-heart failure in pulmonary hypertension. *Chest* 2009;**135**:794–804.
18. Calcutttea A, Chung R, Lindqvist P, Hodson M, Henein MY. Differential right ventricular regional function and the effect of pulmonary hypertension: three-dimensional echo study. *Heart* 2011;**97**:1004–1011.
19. Sandoval J, Bauerle O, Palomar A, Gomez A, Martinez-Guerra ML, Beltran M, Guerrero ML. Survival in primary pulmonary hypertension. Validation of a prognostic equation. *Circulation* 1994;**89**:1733–1744.
20. van de Veerdonk MC, Kind T, Marcus JT, Mauritz GJ, Heymans MW, Bogaard HJ, Boonstra A, Marques KM, Westerhof N, Vonk-Noordegraaf A. Progressive right ventricular dysfunction in patients with pulmonary arterial hypertension responding to therapy. *J Am Coll Cardiol* 2011;**58**:2511–2519.
21. Wauthy P, Pagnamenta A, Vassalli F, Naeije R, Brimiouille S. Right ventricular adaptation to pulmonary hypertension: an interspecies comparison. *Am J Physiol Heart Circ Physiol* 2004;**286**:H1441–H1447.
22. Stevens GR, Garcia-Alvarez A, Sahni S, Garcia MJ, Fuster V, Sanz J. RV dysfunction in pulmonary hypertension is independently related to pulmonary artery stiffness. *JACC Cardiovasc Imaging* 2012;**5**:378–387.
23. Vacchi-Suzzi C, Hahne F, Scheubel P, Marcellin M, Dubost V, Westphal M, Boeglen C, Buchmann-Moller S, Cheung MS, Cordier A, De Benedetto C, Deurinck M, Frei M, Moulin P, Oakeley E, Grenet O, Grevet A, Stull R, Theil D, Moggs JG, Marrer E, Couttet P. Heart structure-specific transcriptomic atlas reveals conserved microRNA–mRNA interactions. *PLoS One* 2013;**8**:e52442.
24. Wong YY, Ruitter G, Lubberink M, Rajmakers PG, Knaapen P, Marcus JT, Boonstra A, Lammertsma AA, Westerhof N, van der Laarse WJ, Vonk-Noordegraaf A. Right ventricular failure in idiopathic pulmonary arterial hypertension is associated with inefficient myocardial oxygen utilization. *Circ Heart Fail* 2011;**4**:700–706.
25. Tuxworth WJ Jr, Shiraishi H, Moschella PC, Yamane K, McDermott PJ, Kuppuswamy D. Translational activation of 5'-TOP mRNA in pressure overload myocardium. *Basic Res Cardiol* 2008;**103**:41–53.
26. Greyson CR, Schwartz GG, Lu L, Ye S, Helmke S, Xu Y, Ahmad H. Calpain inhibition attenuates right ventricular contractile dysfunction after acute pressure overload. *J Mol Cell Cardiol* 2008;**44**:59–68.
27. Archer SL, Gombert-Maitland M, Maitland ML, Rich S, Garcia JG, Weir EK. Mitochondrial metabolism, redox signaling, and fusion: a mitochondria–ROS–HIF-1 α –Kv1.5 O₂-sensing pathway at the intersection of pulmonary hypertension and cancer. *Am J Physiol Heart Circ Physiol* 2008;**294**:H570–H578.
28. Santulli G, Trimarco B, Iaccarino G. G-protein-coupled receptor kinase 2 and hypertension: molecular insights and pathophysiological mechanisms. *High Blood Press Cardiovasc Prev* 2013;**20**:5–12.
29. Bogaard HJ, Natarajan R, Mizuno S, Abbate A, Chang PJ, Chau VQ, Hoke NN, Kraskauskas D, Kasper M, Salloum FN, Voelkel NF. Adrenergic receptor blockade reverses right heart remodeling and dysfunction in pulmonary hypertensive rats. *Am J Respir Crit Care Med* 2010;**182**:652–660.
30. Marcus FI, McKenna WJ, Sherrill D, Basso C, Bauce B, Bluemke DA, Calkins H, Corrado D, Cox MG, Daubert JP, Fontaine G, Gear K, Hauer R, Nava A, Picard MH, Protonotarios N, Saffitz JE, Sanborn DM, Steinberg JS, Tandri H, Thiene G, Towbin JA, Tsatsopoulou A, Wichter T, Zareba W. Diagnosis of arrhythmogenic right ventricular cardiomyopathy/dysplasia: proposed modification of the Task Force Criteria. *Eur Heart J* 2010;**31**:806–814.
31. Fabritz L, Hoogendijk MG, Scicluna BP, van Amersfoort SC, Fortmueller L, Wolf S, Laakmann S, Kreienkamp N, Piccini I, Breithardt G, Noppinger PR, Witt H, Ebnet K, Wichter T, Levkau B, Franke VVW, Pieperhoff S, de Bakker JM, Coronel R, Kirchhof P. Load-reducing therapy prevents development of arrhythmogenic right ventricular cardiomyopathy in plakoglobin-deficient mice. *J Am Coll Cardiol* 2011;**57**:740–750.
32. Lodder EM, Rizzo S. Mouse models in arrhythmogenic right ventricular cardiomyopathy. *Front Physiol* 2012;**3**:221.
33. Marcus JT, Gan CT, Zwanenburg JJ, Boonstra A, Allaart CP, Gotte MJ, Vonk-Noordegraaf A. Interventricular mechanical asynchrony in pulmonary arterial hypertension: left-to-right delay in peak shortening is related to right ventricular overload and left ventricular underfilling. *J Am Coll Cardiol* 2008;**51**:750–757.
34. Hardziyenka M, Surie S, de Groot JR, de Bruin-Bon HA, Knops RE, Rummelink M, Yong ZY, Baan JJ, Bouma BJ, Bresser P, Tan HL. Right ventricular pacing improves haemodynamics in right ventricular failure from pressure overload: an open observational proof-of-principle study in patients with chronic thromboembolic pulmonary hypertension. *Eurpace* 2011;**13**:1753–1759.
35. Handoko ML, Lamberts RR, Redout EM, de Man FS, Boer C, Simonides WS, Paulus WJ, Westerhof N, Allaart CP, Vonk-Noordegraaf A. Right ventricular pacing improves right heart function in experimental pulmonary arterial hypertension: a study in the isolated heart. *Am J Physiol Heart Circ Physiol* 2009;**297**:H1752–H1759.
36. Lourenco AP, Roncon-Albuquerque R Jr, Bras-Silva C, Faria B, Wieland J, Henriques-Coelho T, Correia-Pinto J, Leite-Moreira AF. Myocardial dysfunction and neurohumoral activation without remodeling in left ventricle of monocrotaline-induced pulmonary hypertensive rats. *Am J Physiol Heart Circ Physiol* 2006;**291**:H1587–H1594.
37. Lourenco AP, Vasques-Novoa F, Fontoura D, Bras-Silva C, Roncon-Albuquerque R Jr, Leite-Moreira AF. A Western-type diet attenuates pulmonary hypertension with heart failure and cardiac cachexia in rats. *J Nutr* 2011;**141**:1954–1960.
38. Lourenco AP, Fontoura D, Henriques-Coelho T, Leite-Moreira AF. Current pathophysiological concepts and management of pulmonary hypertension. *Int J Cardiol* 2012;**155**:350–361.
39. Naeije R, van de Borne P. Clinical relevance of autonomic nervous system disturbances in pulmonary arterial hypertension. *Eur Respir J* 2009;**34**:792–794.
40. Lahm T, McCaslin CA, Wozniak TC, Ghumman W, Fadl YY, Obeidat OS, Schwab K, Meldrum DR. Medical and surgical treatment of acute right ventricular failure. *J Am Coll Cardiol* 2010;**56**:1435–1446.
41. Lourenco AP, Vasques-Novoa F, Oliveira-Pinto J, Fontoura D, Roncon-Albuquerque R Jr, Leite-Moreira AF. Haemodynamic and neuroendocrine effects of tezosentan in chronic experimental pulmonary hypertension. *Intensive Care Med* 2012;**38**:1050–1060.
42. Galie N, Hinderliter AL, Torbicki A, Fourme T, Simonneau G, Pulido T, Espinola-Zavaleta N, Rocchi G, Manes A, Frantz R, Kurzyna M, Nagueh SF, Barst R, Channick R, Dujardin K, Kronenberg A, Leconte I, Rainisio M, Rubin L. Effects of the oral endothelin-receptor antagonist bosentan on echocardiographic and doppler measures in patients with pulmonary arterial hypertension. *J Am Coll Cardiol* 2003;**41**:1380–1386.
43. Takimoto E, Champion HC, Li M, Belardi D, Ren S, Rodriguez ER, Bedja D, Gabrielson KL, Wang Y, Kass DA. Chronic inhibition of cyclic GMP phosphodiesterase 5A prevents and reverses cardiac hypertrophy. *Nat Med* 2005;**11**:214–222.
44. Piao L, Fang YH, Cadete VJ, Wietholt C, Urboniene D, Toth PT, Marsboom G, Zhang HJ, Haber I, Rehman J, Lopaschuk GD, Archer SL. The inhibition of pyruvate dehydrogenase kinase improves impaired cardiac function and electrical remodeling in two models of right ventricular hypertrophy: resuscitating the hibernating right ventricle. *J Mol Med (Berl)* 2010;**88**:47–60.
45. Rudski LG, Lai WW, Afilalo J, Hua L, Handschumacher MD, Chandrasekaran K, Solomon SD, Louie EK, Schiller NB. Guidelines for the echocardiographic assessment of the right heart in adults: a report from the American Society of Echocardiography endorsed by the European Association of Echocardiography, a registered branch of the European Society of Cardiology, and the Canadian Society of Echocardiography. *J Am Soc Echocardiogr* 2010;**23**:685–713; quiz 86–88.
46. Urboniene D, Haber I, Fang YH, Thenappan T, Archer SL. Validation of high-resolution echocardiography and magnetic resonance imaging vs. high-fidelity catheterization in experimental pulmonary hypertension. *Am J Physiol Lung Cell Mol Physiol* 2010;**299**:L401–L412.
47. Thibault HB, Kurtz B, Raheer MJ, Shaik RS, Waxman A, Derumeaux G, Halpern EF, Bloch KD, Scherrer-Crosbie M. Noninvasive assessment of murine pulmonary arterial pressure: validation and application to models of pulmonary hypertension. *Circ Cardiovasc Imaging* 2010;**3**:157–163.
48. Reddy S, Zhao M, Hu DQ, Fajardo G, Katznelson E, Punn R, Spin JM, Chan FP, Bernstein D. Physiologic and molecular characterization of a murine model of right ventricular volume overload. *Am J Physiol Heart Circ Physiol* 2013;**304**:H1314–H1327.
49. Fijalkowska A, Kurzyna M, Torbicki A, Szewczyk G, Florczyk M, Pruszczyk P, Szturmowicz M. Serum N-terminal brain natriuretic peptide as a prognostic parameter in patients with pulmonary hypertension. *Chest* 2006;**129**:1313–1321.
50. Kawut SM, Barr RG, Johnson WC, Chahal H, Tandri H, Jain A, Bristow MR, Kizer JR, Bagiella E, Lima JA, Bluemke DA. Matrix metalloproteinase-9 and plasminogen activator inhibitor-1 are associated with right ventricular structure and function: the MESA-RV Study. *Biomarkers* 2010;**15**:731–738.
51. Tutarel O, Dangwal S, Bretthauer J, Westhoff-Bleck M, Roentgen P, Anker SD, Bauersachs J, Thum T. Circulating miR-423_5p fails as a biomarker for systemic ventricular function in adults after atrial repair for transposition of the great arteries. *Int J Cardiol* 2013;**167**:63–66.
52. Piao L, Fang YH, Parikh KS, Ryan JJ, D'Souza KM, Theccanat T, Toth PT, Pogoriler J, Paul J, Blaxall BC, Akhter SA, Archer SL. GRK2-mediated inhibition of adrenergic and dopaminergic signaling in right ventricular hypertrophy: therapeutic implications in pulmonary hypertension. *Circulation* 2012;**126**:2859–2869.
53. Bartelds B, Borgdorff MA, Smit-van Oosten A, Takens J, Boersma B, Nederhoff MG, Elzenga NJ, van Gilst WH, De Windt LJ, Berger RM. Differential responses of the right ventricle to abnormal loading conditions in mice: pressure vs. volume load. *Eur J Heart Fail* 2011;**13**:1275–1282.

54. Schwenke DO, Pearson JT, Mori H, Shirai M. Long-term monitoring of pulmonary arterial pressure in conscious, unrestrained mice. *J Pharmacol Toxicol Methods* 2006;**53**:277–283.
55. Schermuly RT, Dony E, Ghofrani HA, Pullamsetti S, Savai R, Roth M, Sydykov A, Lai YJ, Weissmann N, Seeger W, Grimminger F. Reversal of experimental pulmonary hypertension by PDGF inhibition. *J Clin Invest* 2005;**115**:2811–2821.
56. Correia-Pinto J, Henriques-Coelho T, Magalhaes S, Leite-Moreira AF. Pattern of right ventricular pressure fall and its modulation by afterload. *Physiol Res* 2004;**53**:19–26.
57. Herberg U, Gatzweiler E, Breuer T, Breuer J. Ventricular pressure–volume loops obtained by 3D real-time echocardiography and mini pressure wire—a feasibility study. *Clin Res Cardiol* 2013;**102**:427–438.
58. Sanz J, Garcia-Alvarez A, Fernandez-Friera L, Nair A, Mirelis JG, Sawit ST, Pinney S, Fuster V. Right ventriculo-arterial coupling in pulmonary hypertension: a magnetic resonance study. *Heart* 2012;**98**:238–243.
59. Bishop A, White P, Oldershaw P, Chaturvedi R, Brookes C, Redington A. Clinical application of the conductance catheter technique in the adult human right ventricle. *Int J Cardiol* 1997;**58**:211–221.
60. White PA, Redington AN. Right ventricular volume measurement: can conductance do it better? *Physiol Meas* 2000;**21**:R23–R41.
61. Faber MJ, Dalinghaus M, Lankhuizen IM, Steendijk P, Hop WC, Schoemaker RG, Duncker DJ, Lamers JM, Helbing WA. Right and left ventricular function after chronic pulmonary artery banding in rats assessed with biventricular pressure–volume loops. *Am J Physiol Heart Circ Physiol* 2006;**291**:H1580–H1586.
62. Stenmark KR, Meyrick B, Galie N, Mooi WJ, McMurtry IF. Animal models of pulmonary arterial hypertension: the hope for etiological discovery and pharmacological cure. *Am J Physiol Lung Cell Mol Physiol* 2009;**297**:L1013–L1032.
63. Gomez-Arroyo JG, Farkas L, Alhussaini AA, Farkas D, Kraskauskas D, Voelkel NF, Bogaard HJ. The monocrotaline model of pulmonary hypertension in perspective. *Am J Physiol Lung Cell Mol Physiol* 2012;**302**:L363–L369.
64. Lorenz CH, Walker ES, Graham TP Jr, Powers TA. Right ventricular performance and mass by use of cine MRI late after atrial repair of transposition of the great arteries. *Circulation* 1995;**92**(9 Suppl):II233–II239.
65. Watts JA, Marchick MR, Kline JA. Right ventricular heart failure from pulmonary embolism: key distinctions from chronic pulmonary hypertension. *J Card Fail* 2010;**16**:250–259.
66. Kondo RP, Dederko DA, Teutsch C, Chrast J, Catalucci D, Chien KR, Giles WR. Comparison of contraction and calcium handling between right and left ventricular myocytes from adult mouse heart: a role for repolarization waveform. *J Physiol* 2006;**571**:131–146.
67. Uhlen M, Oksvold P, Fagerberg L, Lundberg E, Jonasson K, Forsberg M, Zwahlen M, Kampf C, Wester K, Hober S, Wernerus H, Bjorling L, Ponten F. Towards a knowledge-based Human Protein Atlas. *Nat Biotechnol* 2010;**28**:1248–1250.
68. Barallobre-Barreiro J, Didangelos A, Schoendube FA, Drozdov I, Yin X, Fernandez-Caggiano M, Willeit P, Puntmann VO, Aldama-Lopez G, Shah AM, Domenech N, Mayr M. Proteomics analysis of cardiac extracellular matrix remodeling in a porcine model of ischemia/reperfusion injury. *Circulation* 2012;**125**:789–802.